

Medical Case Report

HSI Journal (2022) Volume 3 (Issue 1): 341-344. <https://doi.org/10.46829/hsijournal.2022.6.3.1.341-344>Open
Access

Prolapse gastropathy: a rare cause of gastrointestinal bleeding in a child

Taiba J Afaa^{1,3*}, Victor K Etwire², Joycelyn A Dame^{1,3}, Claudia Adja-Sai³,
Kokou H Amegan-Aho⁴

¹ Department of Child Health, University of Ghana Medical School, College of Health Sciences, University of Ghana, Accra, Ghana; ² Department of Surgery, Korle Bu Teaching Hospital, Accra, Ghana; ³ Department of Child Health, Korle-Bu Teaching Hospital, Accra, Ghana; ⁴ Department of Paediatrics, School of Medicine, University of Allied Health Science, Volta Region, Ghana.

Received November 2021; Revised January 2022; March 2022

Abstract

Prolapse gastropathy is a clinical syndrome defined as the invagination of the gastric mucosa into the lower oesophagus due to persistent retching and vomiting. A 15-month-old boy who was previously well presented with repetitive non-bilious vomiting and haematemesis. All laboratory investigations were essentially unremarkable. Upper gastrointestinal endoscopy showed prolapsed gastric mucosa in the oesophagus. The patient was managed with a proton pump inhibitor and cyproheptadine. The lesion had resolved at week 10 follow-up endoscopy. Early upper gastrointestinal endoscopy after adequate resuscitation is required to diagnose vomiting-induced haematemesis due to prolapse gastropathy accurately.

Keywords: Gastrointestinal, endoscopy, children, prolapse, gastropathy

INTRODUCTION

Gastrointestinal bleeding is a common condition in children and can occur anywhere within the gastrointestinal tract [1]. Bleeding occurring anywhere from the oesophagus to the ligament of Treitz is known as upper gastrointestinal bleeding (UGIB) [1]. The commonest presentations of UGIB are haematemesis, melaena and coffee-ground vomiting [2]. The causes of UGIB can be classified based on variceal bleeding and non-variceal bleeding and based on the age at presentation. The non-variceal causes of UGIB include vitamin K deficiency, cow's milk protein allergy, erosive oesophagitis, gastritis, caustic ingestions, peptic ulcer bleeding, coagulation disorders, and vomiting-induced bleeding which include Mallory-Weiss tear and prolapse gastropathy [3]. Prolapse gastropathy is a clinical syndrome defined as the invagination of the gastric mucosa into the lower oesophagus due to persistent retching and vomiting. [4] It was not until 1984 that the term Prolapse Gastropathy Syndrome (PGS) was proposed by Shepherd et al. after reviewing 22 adult cases of vomiting-induced

haematemesis [5]. Prolapse may be associated with an incompetent lower oesophageal sphincter and with repeated invagination or incarceration direct trauma to the gastric mucosa and ulcerations, sometimes ensues [5]. The disrupted mucosal barrier is susceptible to gastric acid which causes vascular permeability and bleeding [4]. Prolapse gastropathy is the cause of UGIB in 2% of adults [6]. Paediatric reports are rare, but recent data shows that prolapse gastropathy in children is commoner than true Mallory-Weiss tear. [2,7] Therefore, most paediatric cases are likely missed without early endoscopy in children presenting with upper gastrointestinal bleeding. We present a case of prolapse gastropathy in a child at a tertiary hospital in Accra, Ghana.

CASE

A 15-month-old boy presented with 19 hours of repetitive non-bilious vomiting. The vomitus progressed from containing food particles to becoming bloody with clots and subsequently to coffee ground. He had a low-grade fever at 37.8 °C two days before presentation, which was relieved with a single dose of paracetamol. There was no cough, coryza, rhinorrhoea or bleeding from other sites. There was no history of ingestion of a corrosive substance or herbal medication. He was delivered at term with no history of neonatal events. His development had been normal.

* Corresponding author

Email: taibaafaa@yahoo.com

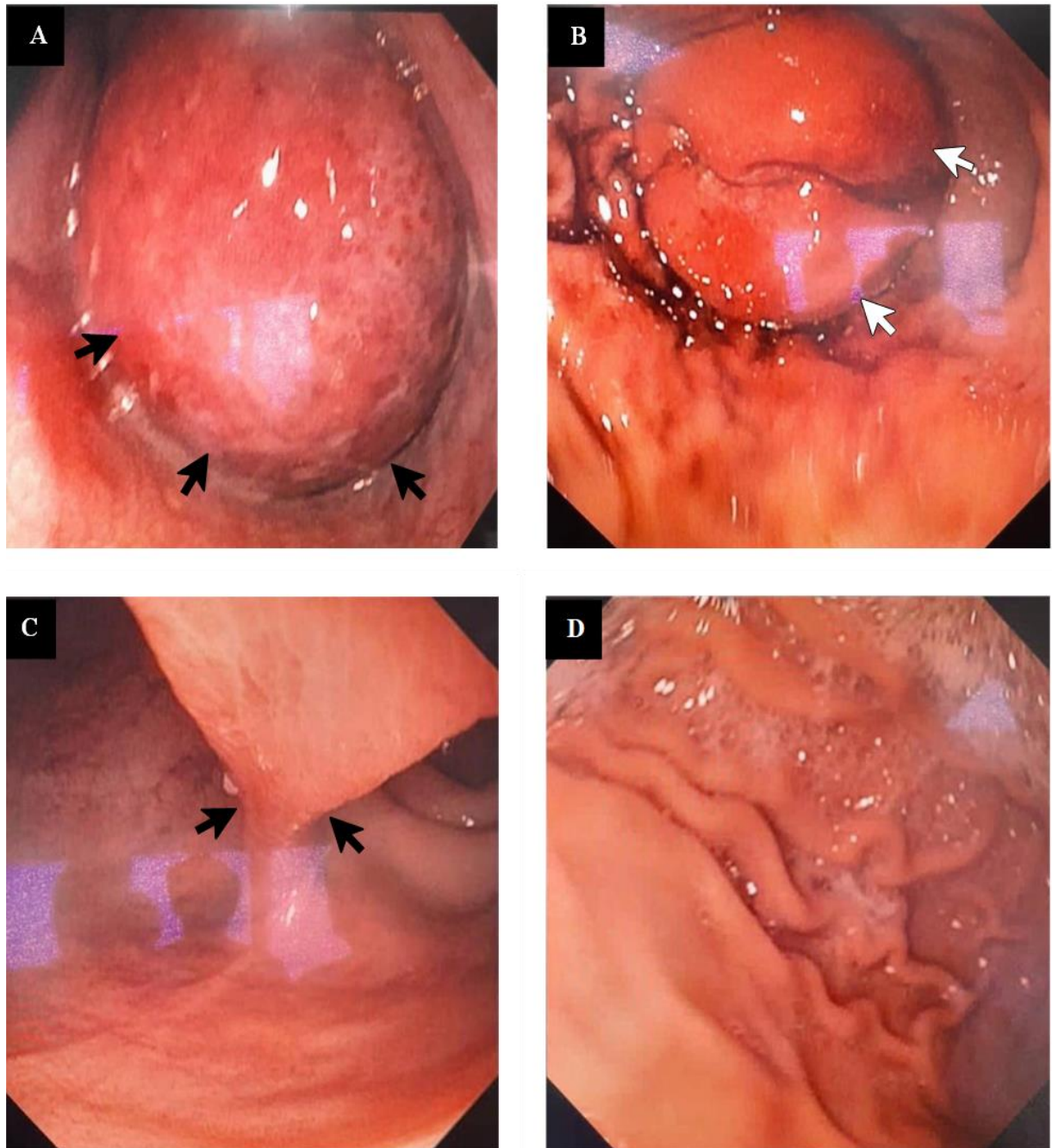


Plate 1: Prolapsed Gastropathy. (A) Invagination of the stomach into the esophagus with erythematous patches on the gastric mucosa (black arrows). (B) Redundant prolapsed gastric mucosa (double white arrows). (C) Flattened gastric prolapsed (black arrows). (D) Disappearance of the prolapsed after 8 weeks of treatment

On examination, he was irritable, not pale, anicteric, afebrile, not clubbed, no lymphadenopathy, and no oedema. He was well hydrated and had no stigmata of chronic liver disease. The heart rate was 161 beats per minute, apex beat was in the 4th left intercostal space mid-clavicular line. The

blood pressure was 97/72 mmHg. The abdomen was flat, moved with respiration non-tender, soft, and with no palpable masses or ascites. Bowel sounds were present and normal. There was no blood on the digital rectal examination. Differential diagnoses of acute

gastroenteritis with Mallory-Weiss tear secondary to food poisoning were considered. Laboratory data showed haemoglobin of 11.7 g/dL, platelets of 267,000/mm³, sodium of 132 mmol/L, potassium of 4.4 mmol/L, urea of 2.0 mmol/L, and creatinine of 19 mmol/L. The clotting profile was normal with an Activated Partial Thromboplastin Clotting Time of 26, Prothrombin Time of 11.3 and the International Normalized Ratio of 1.01. Liver function was also normal with an aspartate aminotransferase reading of 57 IU/L, alanine transaminase of 31 IU/L, alkaline phosphatase of 198 IU/L, Gamma-glutamyl Transferase of 25 IU/L, and an albumin reading of 44 g/L. Other normal laboratory results were hepatitis B and C viral screen, antigen test for *Plasmodium falciparum* and blood film for malaria parasites, blood culture, urinalysis and urine culture, and abdominopelvic ultrasound. His initial treatment included intravenous (IV) maintenance of 0.45% dextrose saline with IV esomeprazole 500 µg/kg/day, IV granisetron 0.5 mg 12 hourly and IV ceftriaxone 50 mg/kg daily, but nothing by mouth. The vomiting persisted, but the volumes gradually reduced over the first 3 days. On the fourth day, the patient had an upper gastrointestinal endoscopy that revealed the prolapsed gastric mucosa in the oesophagus with the “stalk” initially noticed in the stomach (Plate 1a and 1c). The invagination immediately flattened out during the endoscopy (Plate 1b). There were erosions at the lower oesophagus with the prolapsed gastric mucosa showing erythematous patches. Biopsies were taken and histology showed acute gastritis. After 48 hours of negative blood culture report, IV ceftriaxone was stopped. The patient was discharged on the 5th day with oral esomeprazole of 10 mg daily.

Three weeks later, the patient was brought in again with multiple episodes of haematemesis of 10 hours duration. Laboratory data showed haemoglobin 10.0 g/dL, platelets 262,000/mm³, serum sodium 146 mmol/L, potassium 4.7 mmol/L, urea 2.0 mmol/L and creatinine 28 mmol/L. A nasogastric tube was passed to empty the stomach. He was administered IV esomeprazole 20 mg daily, and IV metoclopramide 1.5 mg eight hourly. Intramuscular promethazine was later added as the vomiting continued. The vomiting ceased on the third day and feeding improved gradually. He was later discharged on syrup cyproheptadine 2 mg daily. Since the last episode, he had been well for 10 weeks with no recurrence of vomiting or haematemesis. A repeat endoscopy showed a complete resolution of the prolapsed mucosa (Plate 1d).

DISCUSSION

Axon and Clarke first reported lesions suggestive of prolapse gastropathy in 3 adults in 1975 [8]. The most available paediatric data are case reports. The largest studies were recently published in the United States of America (USA) and Iran. A retrospective study in the USA over 11 years period from 1998 through to 2009 in a

gastroenterology centre among children from birth to 17 years showed that prolapse gastropathy was the commonest cause of UGIB in 12.7% [2]. The Iranian study was a cross-sectional study conducted over 4 years [7]. Of the 113 children, less than 18 years who presented with UGIB, 21 (18.6%) were diagnosed with prolapse gastropathy. The highest proportion in the Iranian study may be explained by the study design. Two retrospective studies were done in Nigeria [9] and Uganda [10] in children who had endoscopy due to UGIB and did not report any case of prolapse gastropathy. The longer the waiting time for endoscopy (> 48 hours), the less likely a cause can be found [11]. Vomiting-induced haematemesis in children is usually attributed to Mallory-Weiss tear (MWT) [12]. However, recent studies have shown that MWT is less common than PGS [2,7]. Moreover, children are less likely than adults to develop MWT due to a greater tensile strength of the gastrointestinal tract hence a higher force is required for the gastrointestinal tract to tear after vomiting. Excessive vomiting is the main cause of PGS. Some common causes of vomiting in children include viral gastroenteritis, urinary tract infection, respiratory tract infection, and food poisoning, among others [13]. In 2011, Alkhouri et al. in the USA reported the case of a 9-year-old boy with PGS caused by zonisamide induced-vomiting [14]. The vomiting stopped when the medication was withdrawn. As in the index case with infection-induced vomiting, Pohl et al., 2011, also reported a child with PGS due to viral gastroenteritis [15].

In this case, prolapse gastropathy was diagnosed due to the availability and expertise for paediatric endoscopy, as this diagnosis is not commonly made in children. Unfortunately, endoscopy is not widely available for children in developing countries. This in addition to the need for sedation or anaesthesia during the procedure may explain why PGS is less diagnosed in our context. Just like it has been stated in literature [16], the finding at endoscopy, in this case, is typical of prolapse gastropathy and what made this more interesting was the visualization of the incarcerated gastric mucosa in the oesophagus (Plate 1a). No other lesions were found to explain the cause of the haematemesis, as the erosion seen is a consequence of the repeated incarceration of the gastric mucosa in the lower oesophagus. The principle of management of PGS is to treat the underlying cause of vomiting. Cyproheptadine is shown to be very safe and effective in treating vomiting in young children [17] and this was used successfully to stop vomiting in this case. A proton pump inhibitor was used because of the presence of erosions in the oesophagus. It is important to recognize and diagnose prolapse gastropathy as this is an uncommon cause of gastrointestinal bleeding which if not managed appropriately may lead to severe blood loss and its associated complications.

Conclusion

Early upper gastrointestinal endoscopy after adequate resuscitation is required to accurately diagnose vomiting-induced haematemesis due to prolapse gastropathy.

DECLARATIONS

Ethical considerations

Informed consent was obtained from the patient's caregivers for this report. This report does not contain information that could lead to the traceability of the patient.

Consent to publish

All authors agreed to the content of the final paper.

Funding

None

Competing Interests

No potential conflict of interest was reported by the authors.

Author contributions

TJA, VKE, JAD, CA, KHA all contributed to the management of the cases, drafting and final review of the manuscript. All authors agreed on the final content of the manuscript.

Acknowledgements

The authors are grateful to the patient for consenting to this publication. The authors are also grateful to all staff who were involved in the management of the patient.

Availability of data

All relevant information is provided in the manuscript. The published information is available from the corresponding author upon a reasonable request.

REFERENCES

- Owensby S, Taylor K, Wilkins T (2015) Diagnosis and management of upper gastrointestinal bleeding in children. *J Am Board Fam Med.* 28:134–145
- Cleveland K, Ahmad N, Bishop P, Nowicki M (2012) Upper gastrointestinal bleeding in children: An 11-year retrospective endoscopic investigation. *World J Pediatr.* 8: 123-128. <https://doi.org/10.1007/s12519-012-0350-8>
- Wilkins T, Khan N, Nabh A, Schade RR (2012) Diagnosis and management of upper gastrointestinal bleeding. *Am Fam Physician* 85:469–476. <https://doi.org/10.3238/arztebl.2008.0085>
- Chen YL (1990) Mechanical gastritis involving the cardia: The trauma of retching and vomiting. *J Clin Gastroenterol* 12:63–66. <https://doi.org/10.1097/00004836-199002000-00016>
- Shepherd HA, Harvey J, Jackson A, Colin-Jones DG (1984) Recurrent retching with gastric mucosal prolapse - A proposed prolapse gastropathy syndrome. *Dig Dis Sci* 29:121–128. <https://doi.org/10.1007/BF01317052>
- Kuwano H, Morita M, Mori M, Matsuura H, Sugimachi K, Haraguchi Y (1991) Endoscopic evidence of gastric mucosal prolapse with retching and vomiting. *Gastrointest Endosc* 37:585–586
- Jafari SA, Kiani MA, Kianifar HR, Mansooripour M, Heidari E, Khalesi M (2018) Etiology of gastrointestinal bleeding in children referred to pediatric wards of Mashhad hospitals, Iran. *Electron Physician* 10:6341–6345. <https://doi.org/10.19082/6341>
- Axon ATR, Clarke A (1975) Haematemesis: A New Syndrome? *Br Med J* 1:511. <https://doi.org/10.1136/bmj.1.5956.511-b>
- Adeniyi OF, Lesi OA, Odeghe EA, Adekola O, Oduwale OA (2016) Upper gastrointestinal endoscopy in children: The Lagos University Teaching Hospital experience. *SAJCH South African J Child Heal* 10:207–210. <https://doi.org/10.7196/SAJCH.2016.v10i4.1116>
- Alema ON, Martin DO, Okello TR (2012) Endoscopic findings in upper gastrointestinal bleeding patients at Lacor hospital, northern Uganda. *Afr Health Sci* 12:518–521. <https://doi.org/10.4314/ahs.v12i4.19>
- Thomson M, Tringali A, Dumonceau JM, Tavares M, Tabbers MM, Furlano R, Spaander M, Hassan C, Tzvinikos C, Ijsselstijn H, Viala J, Dall'Oglio L, Benninga M, Orel R, Vandenplas Y, Keil R, Romano C, Brownstone E, Hlava Š, Gerner P, Dolak W, Landi R, Huber WD, Everett S, Vecsei A, Aabakken L, Amil-Dias J, Zambelli A (2017) Paediatric gastrointestinal endoscopy: European society for paediatric gastroenterology hepatology and nutrition and European society of gastrointestinal endoscopy guidelines. *J Pediatr Gastroenterol Nutr* 64:133–153. <https://doi.org/10.1097/MPG.0000000000001408>
- Yu PP, White D, Iannuccilli EA (1982) The Mallory-Weiss syndrome in the pediatric population. Rare condition in children should be considered in the presence of hematemesis. *R I Med J* 65:73–74
- Shields TM, Lightdale JR (2018) Vomiting in children. *Pediatr Rev* 39:342–358. <https://doi.org/10.1542/pir.2017-0053>
- Alkhoury RH, Desai S, Gelfond D, Baker S (2011) Prolapse gastropathy. *J Pediatr Gastroenterol Nutr* 52:477–480. <https://doi.org/10.1097/MPG.0b013e3181fa0717>
- Pohl JF, Melin-Aldana H, Rudolph C (2000) Prolapse gastropathy in the pediatric patient. *J Pediatr Gastroenterol Nutr* 30:458–460. <https://doi.org/10.1097/00005176-200004000-00022>
- Hopp GD, Brown L, Singh T, Parker A (2021) A Case of Prolapsed Gastropathy Syndrome Presenting as Hematemesis and Acute Blood Loss Anemia. *Cureus* 13:e12563. <https://doi.org/10.7759/cureus.12563>
- Rodriguez L, Diaz J, Nurko S (2013) Safety and efficacy of cyproheptadine for treating dyspeptic symptoms in children. *J Pediatr.* <https://doi.org/10.1016/j.jpeds.2012.12.096>

Thank you for publishing with

